



# Bella

11-year-old | Female Spayed | Golden Retriever | 53 lbs

Cancer Screening in a Geriatric Golden Retriever

ONCOK9<sup>®</sup> by PetDX<sup>™</sup>

## Presentation

### USE CASE

#### Screening

- ✓ Age 7 and Older
- ✓ Breed Predisposed to Cancer

### CLINICAL DETAILS

Bella presented for a routine wellness visit. Her physical exam showed no clinical signs of cancer.

### WHY ONCOK9 WAS PERFORMED

Bella had no signs of cancer but was over age 7 and of a predisposed breed. OncoK9 was performed as part of her wellness and preventive care evaluation.

## OncoK9<sup>®</sup> Result

### CANCER SIGNAL



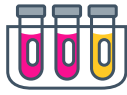- A *Cancer Signal Detected* result significantly increases the likelihood that cancer is present, but does not confirm the presence of cancer. **This result should not be used as the sole basis for making important decisions such as treatment or euthanasia.**
- A confirmatory cancer evaluation should be performed to establish a definitive diagnosis.

Due to a **Cancer Signal Detected** OncoK9 result, a Confirmatory Cancer Evaluation was performed.

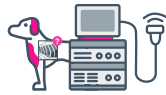## Confirmatory Cancer Evaluation



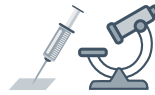EXAM



LABORATORY



IMAGING



SAMPLING

## Cancer Workup & Findings

- Abdominal ultrasound – hypoechoic mass in the liver; mottled spleen and liver
  - When shaving for ultrasound, multiple red-black miliary skin lesions noted
- Oncologist visit scheduled 4 weeks out
- Additional dermal lesions developed while awaiting oncology appointment
  - Biopsied lesions (pinna + perianal area + ventrum)

**Diagnosis from histopathology: Hemangiosarcoma**

## Case Takeaways/Outcome

### VETERINARIAN


OncoK9 detected the presence of cancer in a patient with no clinical signs, and helped shorten the path to diagnosis by providing lead time for imaging scheduling.

### OWNER

OncoK9 gave Bella's owners the time to prepare and the option to start therapy.

### PATIENT

Bella was able to get started on therapy prior to developing clinical signs, potentially giving her prolonged good quality of life.



# Bella

11-year-old | Female Spayed | Golden Retriever | 53 lbs

Cancer Screening in a Geriatric Golden Retriever

ONCOK9<sup>®</sup> by PetDx<sup>®</sup>

## Case Summary

- 11yo FS asymptomatic Golden Retriever with no suspicion of cancer
- OncoK9<sup>®</sup>: **Cancer Signal Detected**
- Confirmatory Cancer Evaluation recommended
- Skin masses & miliary red-black skin nodules noted, confirmed to be hemangiosarcoma on histopathology
- Client pursued oncology consultation and elected to begin palliative care

ONCOK9<sup>®</sup> by PetDx<sup>®</sup>

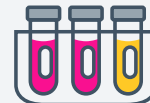## Confirmatory Cancer Evaluation

May include any or all of the following:



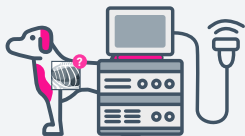
### EXAM

- Thorough clinical history
- Thorough physical exam
  - Including oral and rectal exam



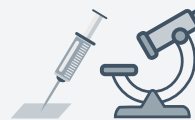### LABORATORY

- CBC and Chemistry
- Urinalysis



### IMAGING

- Thoracic radiographs – 3 views
- Abdominal imaging – ultrasound preferred
- Radiographs of localized areas of bone or joint pain, if present



### SAMPLING

- Tissue sampling of any detected masses or enlarged lymph nodes for pathological analysis

In some cases, advanced imaging (such as CT and/or MRI) may be indicated.



Scan the QR code or visit [petdx.science/case-studies](https://petdx.science/case-studies) to browse additional case studies.

✉ [sales@petdx.com](mailto:sales@petdx.com) ☎ (833) 464-7297 🖱 [www.petdx.com](https://www.petdx.com)

©2022 PetDx, Inc. All rights reserved | All trademarks are property of their respective owners. | 05112022